INTRODUCTION TO GLAUCOMA

1. **Aqueous outflow**
   - **Anatomy**
   - **Physiology**
2. **Classification of secondary glaucoma**
3. **Tonometers**
4. **Gonioscopy**
5. **Anatomy of retinal nerve fibres**
6. **Optic nerve head**
7. **Humphrey perimetry**

Aqueous outflow

Anatomy	Physiology
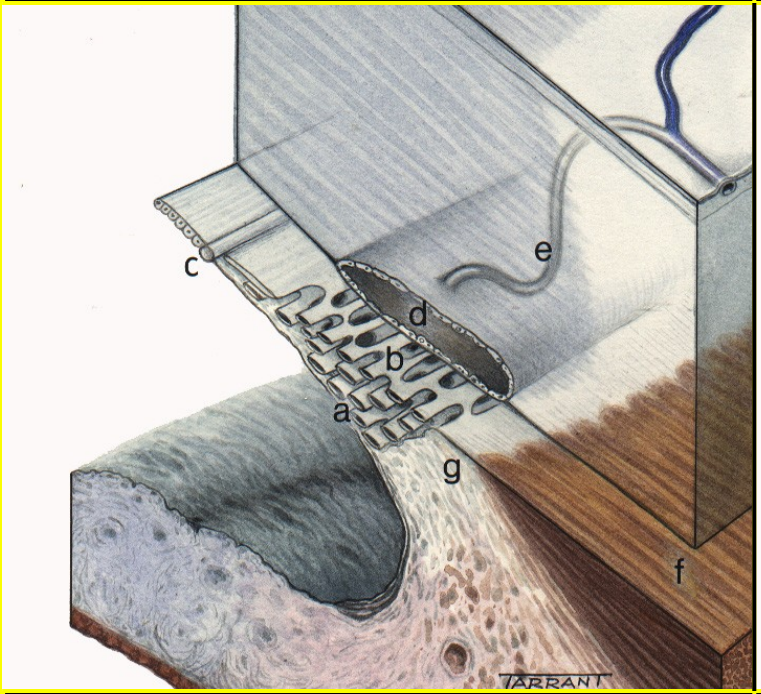	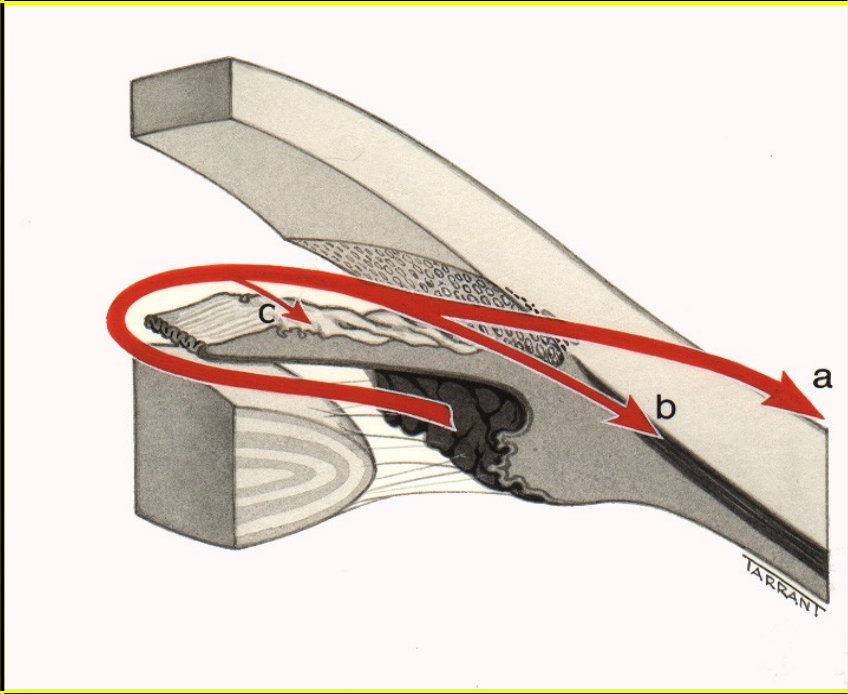
a - Uveal meshwork b - Corneoscleral meshwork c - Schwalbe line d - Schlemm canal e - Collector channels f - Longitudinal muscle of ciliary body g - Scleral spur	a - Conventional outflow b - Uveoscleral outflow c - Iris outflow

Classification of secondary glaucomas

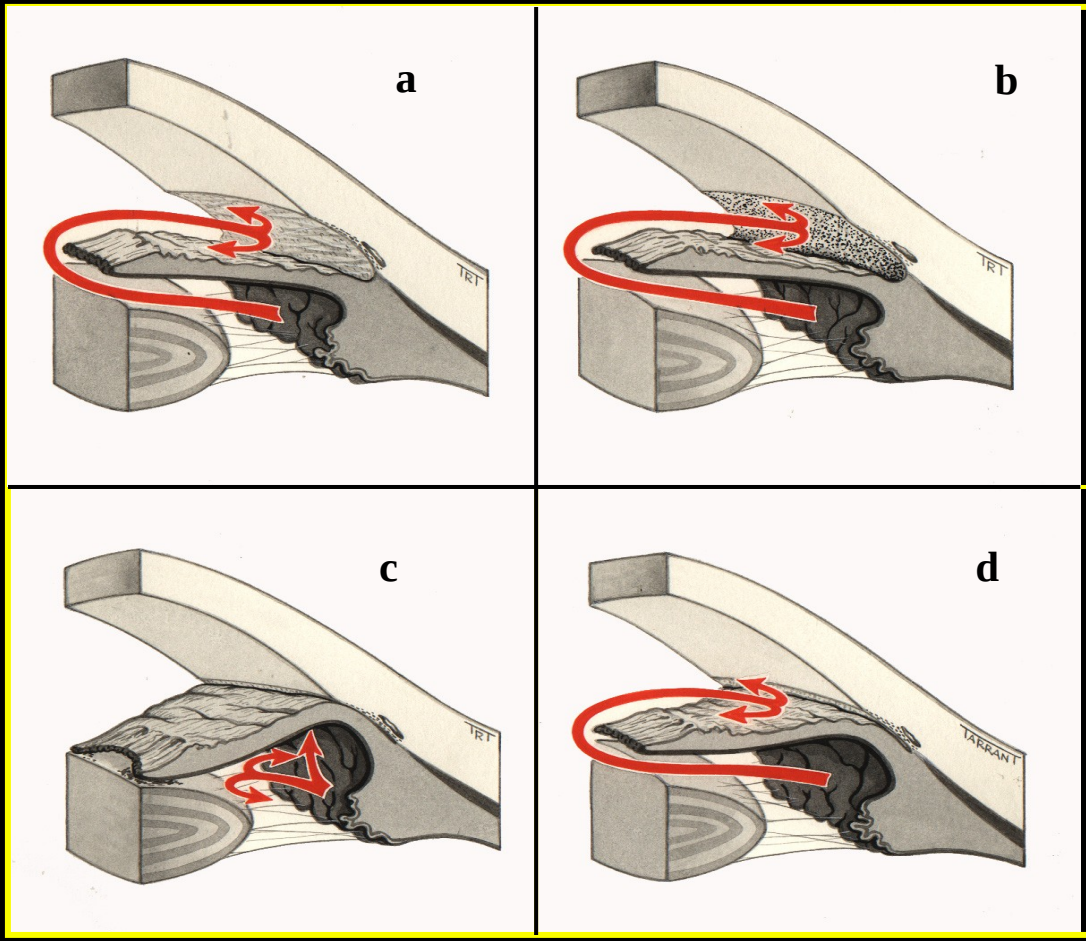

Open-angle

a. *Pre-trabecular* - membrane over trabeculum

b. *Trabecular* - ‘clogging up’ of trabeculum

Angle-closure

c. *With pupil block* - seclusio pupillae and iris bombé

d. *Without pupil block* - peripheral anterior synechiae

Tonometers

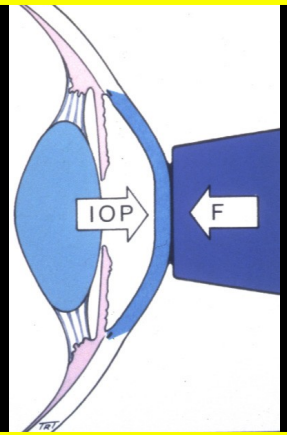

Goldmann

Contact applanation

Perkins

Portable contact applanation

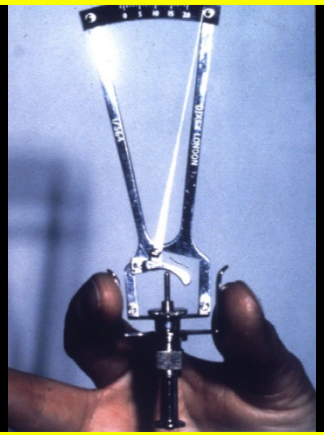

Schiotz

Contact indentation

Air-puff

Non-contact indentation

Pulsair 2000 (Keeler)

Portable non-contact applanation

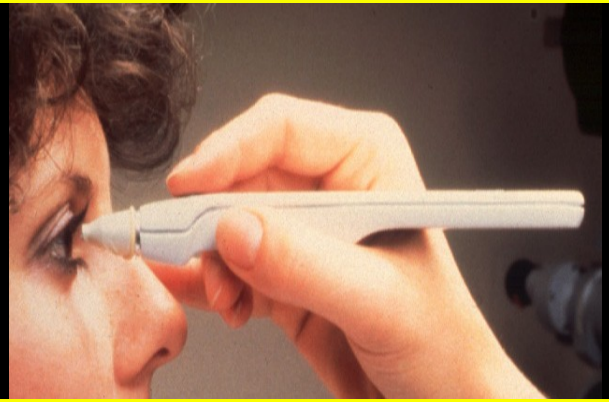

Tono-Pen

portable contact applanation

Goniolenses

Goldmann	Zeiss
	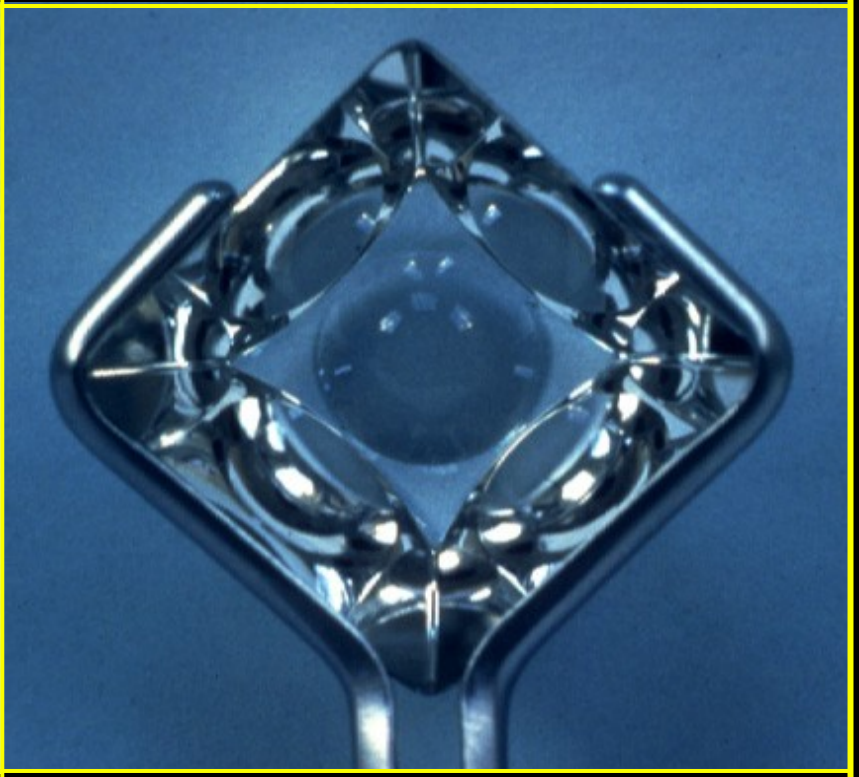
· Single or triple mirror · Contact surface diameter 12 mm · Coupling substance required · Suitable for ALT · Not suitable for indentation gonioscopy	· Four mirror · Contact surface diameter 9 mm · Coupling substance not required · Not suitable for ALT · Suitable for indentation gonioscopy

Indentation gonioscopy

Differentiates ‘appositional’ from ‘synechial’ angle closure

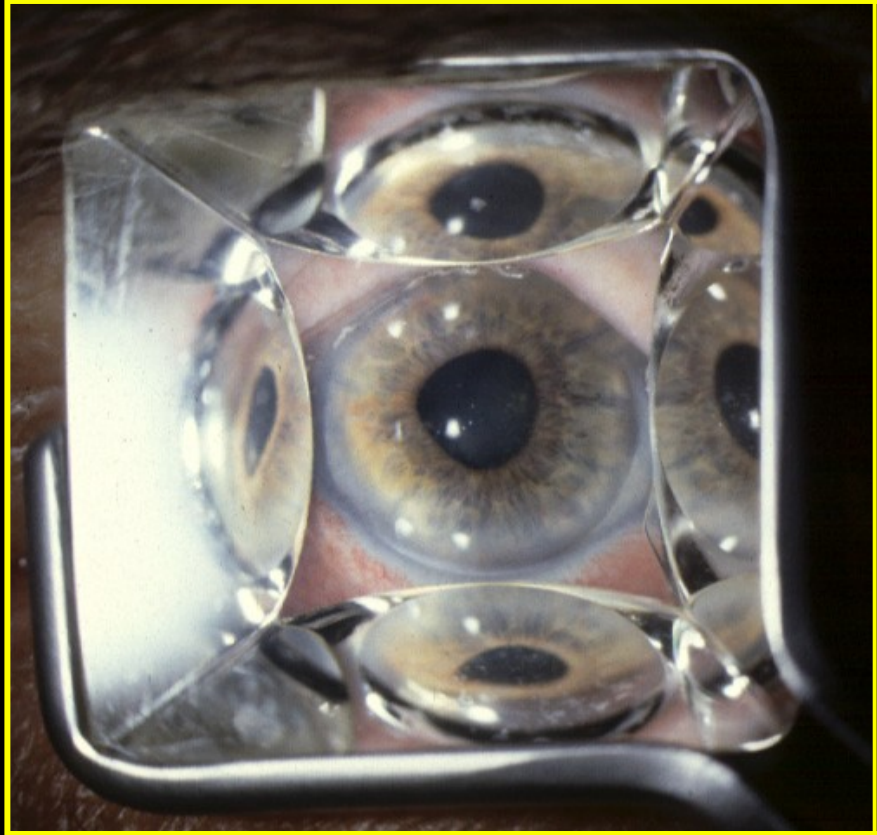

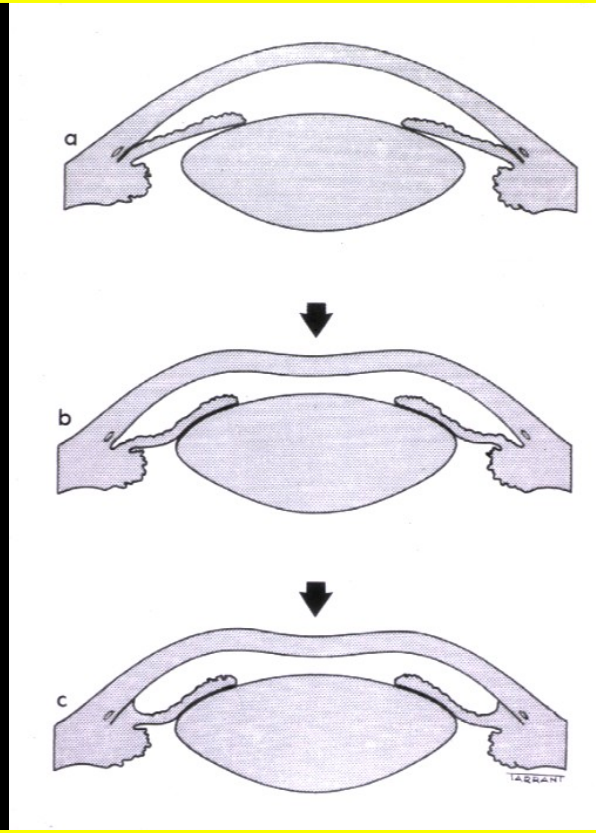

Press Zeiss lens posteriorly against cornea	**Aqueous is forced into periphery of anterior chamber**

Indentation gonioscopy in iridocorneal contact

During indentation	Before indentation
· Part of angle is forced open · Part of angle remains closed by PAS	· Complete angle closure · Apex of corneal wedge not visible

Angle structures

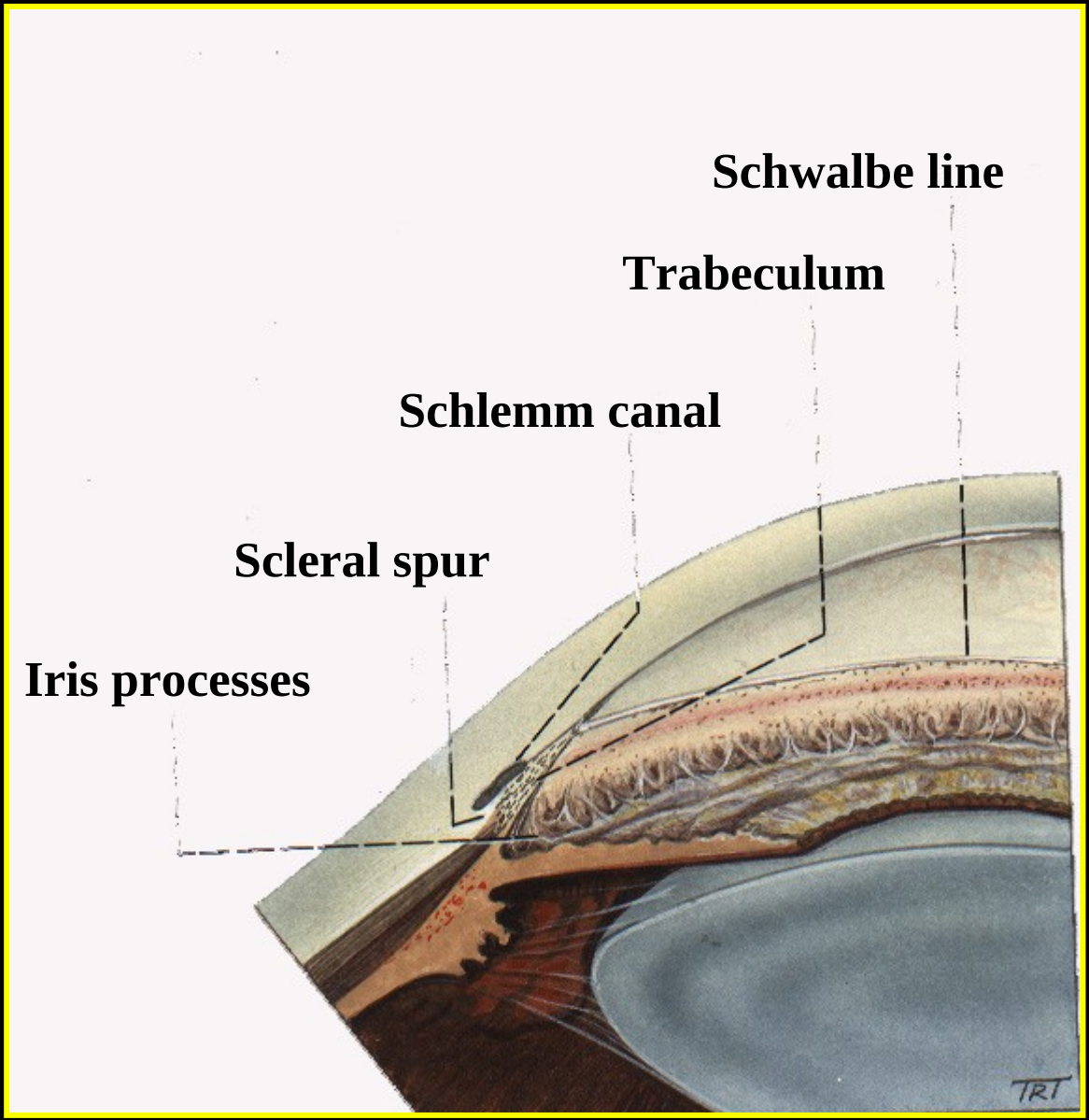

Shaffer grading of angle width

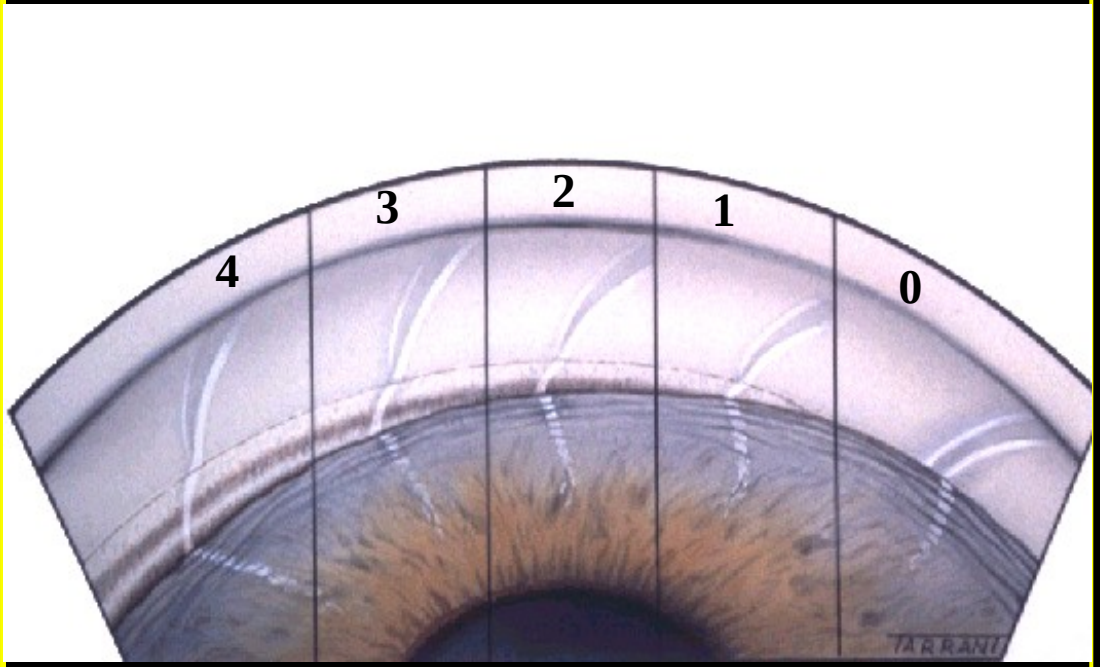

Grade 4 (35-45°)
- Ciliary body easily visible

Grade 3 (25-35°)
- At least scleral spur visible

Grade 2 (20°)
- Only trabeculum visible
- Angle closure possible but unlikely

Grade 1 (10°)
- Only Schwalbe line and perhaps top of trabeculum visible
- High risk of angle closure

Grade 0 (0°)
- Iridocorneal contact present
- Apex of corneal wedge not visible
- Use indentation gonioscopy

Anatomy of retinal nerve fibres

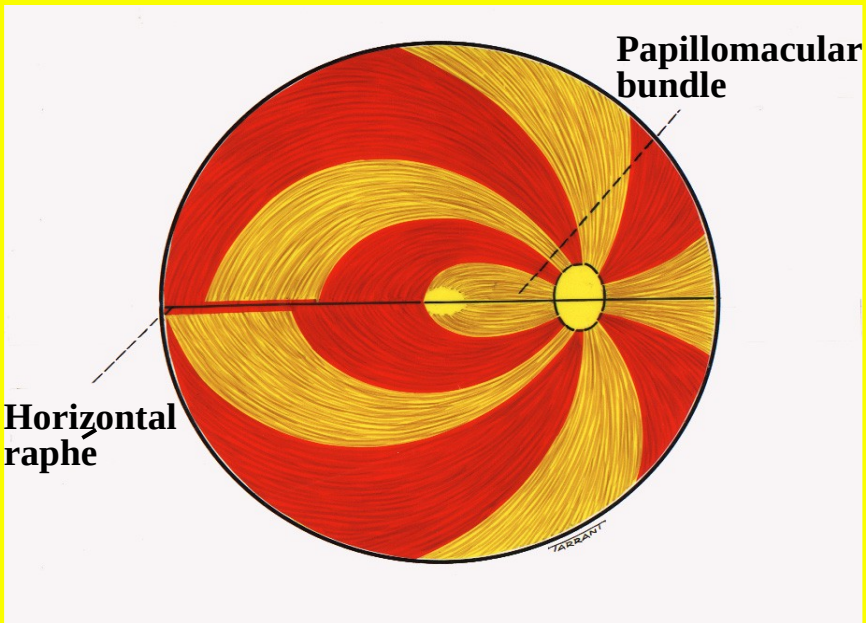

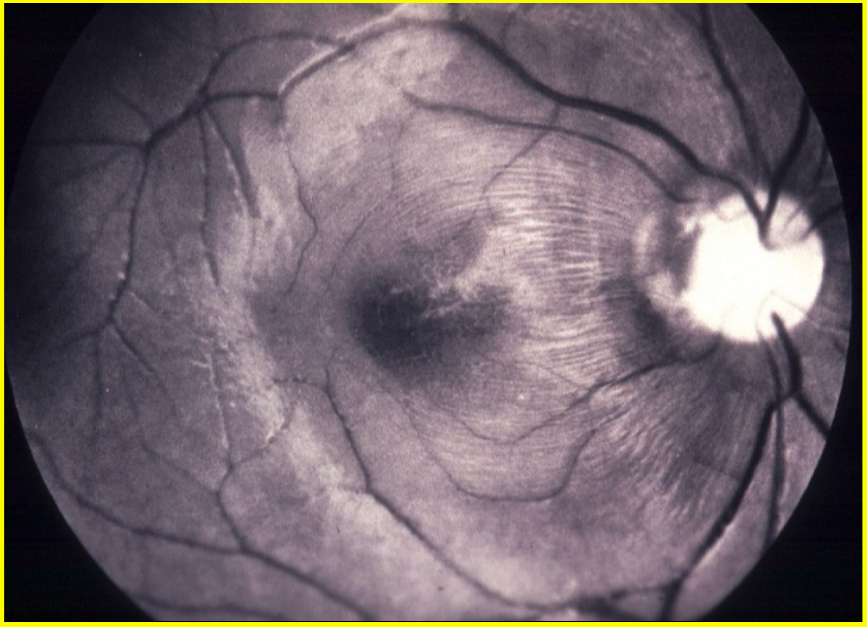

Optic nerve head

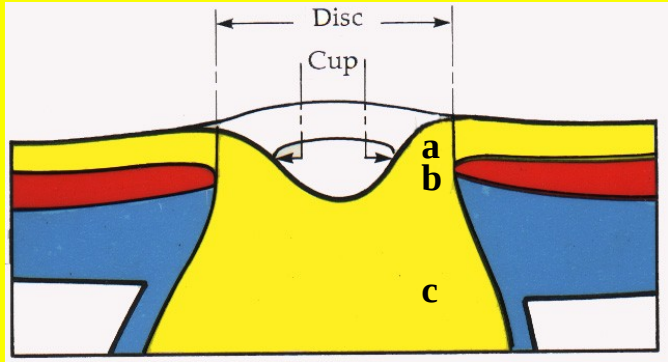

Small physiological cup

a - Nerve fibre layer

b - Prelaminar layer

c - Laminar layer

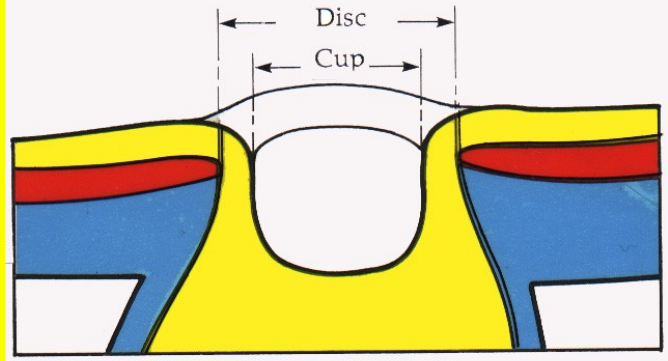

Large physiological cup

- Normal vertical cup-disc ratio is 0.3 or less
- 2% of population have cup-disc ratio > 0.7
- Asymmetry of 0.2 or more is suspicious

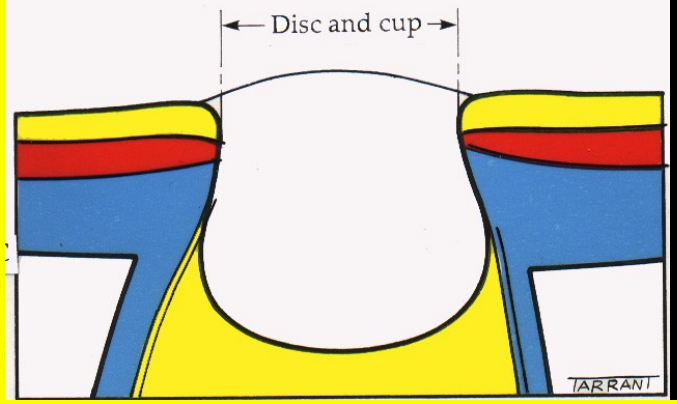

Total glaucomatous cupping

Types of physiological excavation

Small dimple central cup

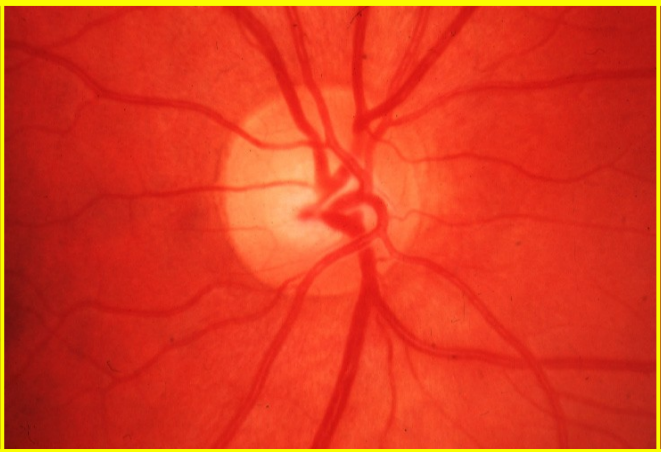

Larger and deeper punched-out central cup

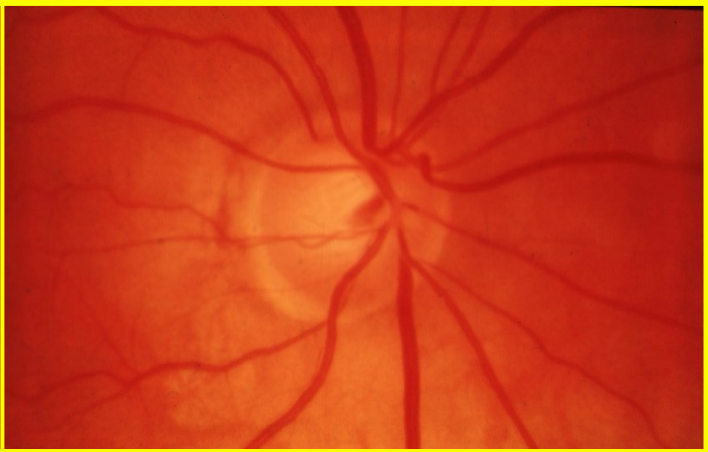

Cup with sloping temporal wall

Pallor and cupping

Pallor - maximal area of colour contrast

Cupping - bending of small blood vessels crossing disc

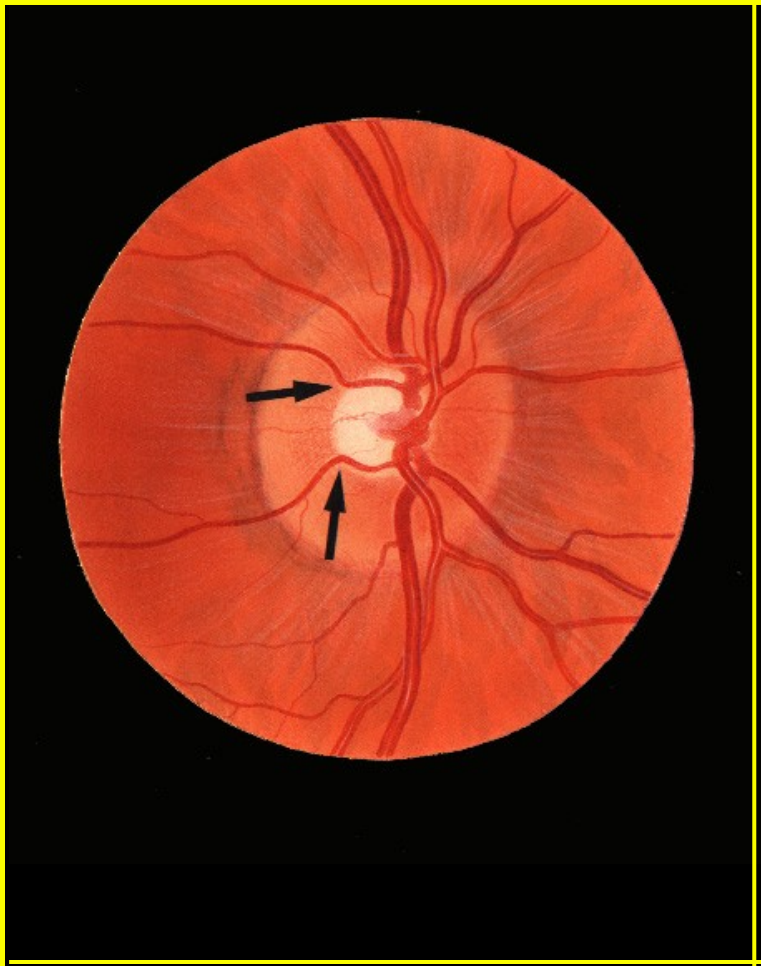

Cupping and pallor correspond

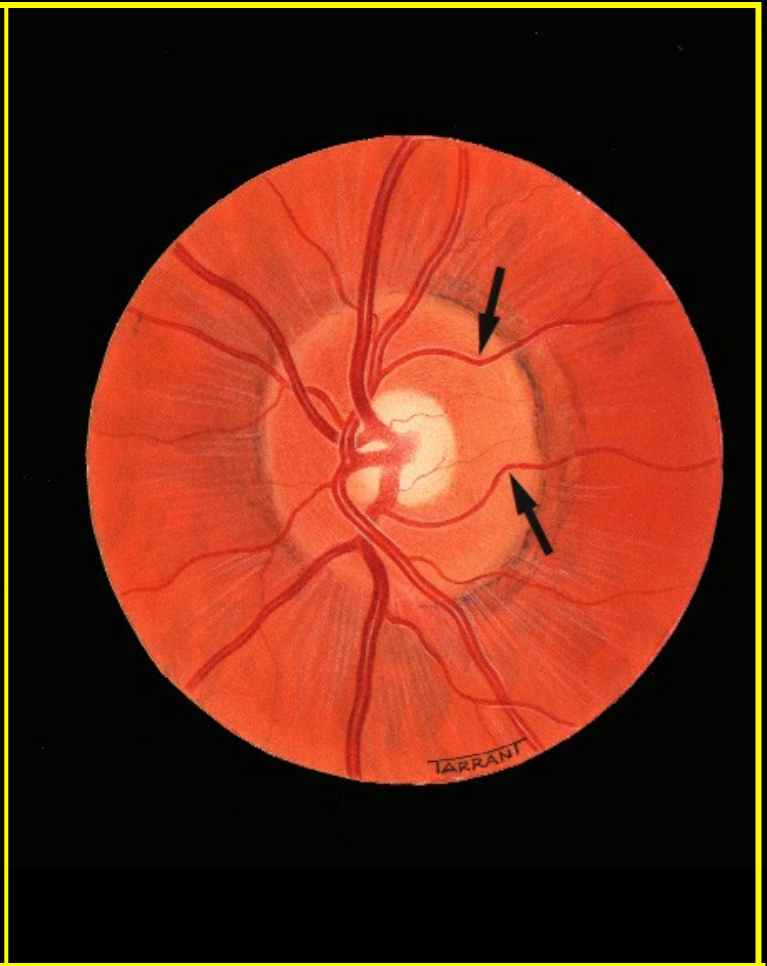

Cupping is greater than pallor

Humphrey perimetry

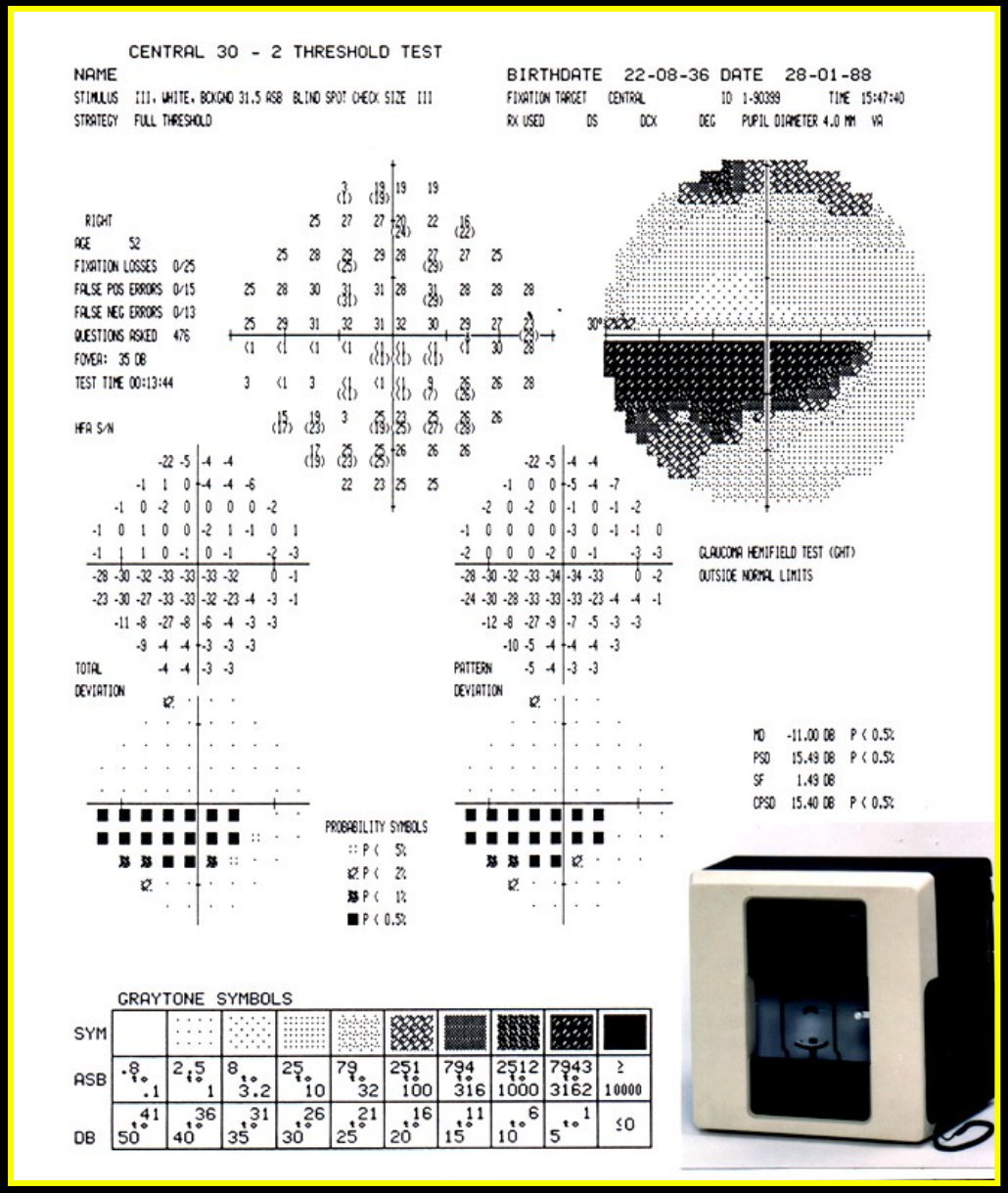

Reliability Indices

1. **Fixation losses**
   - Detected by presenting stimuli in blind spot
2. **False positives**
   - Stimulus accompanied by a sound
   - High score suggests a ‘trigger happy’ patient
3. **False negatives**
   - Failure to respond to a stimulus 9 dB brighter than previously seen at same location
   - High score indicates inattention, or advanced field loss

Deviations

1. Total

- Upper numerical display shows difference (dB) between patient's results and age-matched normals
- Lower graphic display shows these differences as grey scale

2. Pattern

- Similar to total deviation
- Adjusted for any generalized depression in overall field

Global Indices

1. **Mean deviation** (elevation or depression)
   - Deviation of patient's overall field from normal
   - *p* values are < 5%, < 2%, < 1% and < 0.5%
   - The lower the *p* value the greater the significance
2. **Pattern standard deviation**
   - Departure of visual field from age-matched normals
3. **Short-term fluctuation**
   - Consistency of responses
   - 2 dB or less indicates reliable field
   - > 3 dB indicates either unreliable or damaged field
4. **Corrected pattern standard deviation**
   - Departure of overall shape of patient's hill of vision from age-matched normals